

Marginal Mandibular Nerve Weakness Due to a Giant Osteoma: A Case Report

Mohammed Oday Falih B.D.S, F.I.B.M.S.^{1*}, Hanan Amanuel Qas Marrogy²

¹Oral and Maxillofacial Surgeon, Department of Maxillofacial Surgery at Alwasity Teaching Hospital. Iraq/Baghdad.

²Oral and maxillofacial surgery resident.

***Corresponding Author:** Falih MO B.D.S, F.I.B.M.S, Oral and Maxillofacial Surgeon, Department of Maxillofacial Surgery at Alwasity Teaching Hospital. Iraq/Baghdad.

Received date: 05 May 2023; **Accepted date:** 25 May 2023; **Published date:** 29 May 2023

Citation Falih MO, Marrogy HAQ (2023) Marginal Mandibular Nerve Weakness Due to a Giant Osteoma: A Case Report. J Med Case Rep Case Series 4(09): <https://doi.org/10.38207/JMCRCS/2023/MAY04090353>

Copyright: © 2023 Mohammed Oday Falih B.D.S, F.I.B.M.S. This is an open-access article distributed under the terms of the Creative Commons Attribution License, which permits unrestricted use, distribution, and reproduction in any medium, provided the original author and source are credited.

Abstract

Osteomas of the jaw are rare, benign, asymptomatic, slow-growing, and progressive osteogenic neoplasms, primarily located in the angle of the mandible. These neoplasms can grow to enormous sizes and exert constant pressure over the nerve, leading to nerve weakness, affecting its function, and causing cosmetic problems. The facial nerve is associated with different facial expressions, and its involvement in large neoplasms is highly uncommon and requires early recognition and intervention to prevent permanent damage. This study aims to document a rare clinical presentation associated with asymmetry in a patient's smile due to unilateral weakness of the marginal mandibular branch of the facial nerve. The evaluation of the improvement in the patient's smile was done using the Sunnybrook Facial Grading System to guide us in observing the healing process of the nerve after osteoma removal.

Keywords: Osteoma, multiple osteomas, facial nerve weakness, Gardner's syndrome, the Sunnybrook Facial Grading System.

Introduction

Neoplasms are described as masses that have developed due to abnormal cell or tissue growth that is uncoordinated with normal tissue development [1]. Jaw neoplasms can be odontogenic or nonodontogenic related based on their origin; they can present as hard or soft based on their contents; and they can be benign or malignant based on their behavior, pattern, and cellular structure. Nonodontogenic neoplasms of the jaws comprise bone or cartilage, fibrous tissue, osteoid, cartilage, and cementum. Osteomas are benign osteogenic neoplasms formed by cancellous or compact bone proliferation or both. There are three different types: central, peripheral, and extra-skeletal. Commonly observed in young adults between the second and fifth decades, it has an equal incidence among men and women [2]. These neoplasms may arise in the maxilla or mandible, particularly at the angle and lingual aspect of the mandible in the premolar and molar areas. Periosteal osteomas appear as polypoid or sessile masses on the bone surface, whereas endosteal osteomas may not be clinically apparent unless they are large enough to cause expansion [3]. These osseous neoplasms are typically slow-growing, but they occasionally exhibit progressive growth and result in bone expansion, facial deformity, and dysfunction [2]. Osteoma along the nerve pathway can exert pressure on the nerve that passes close to the enlarged mass, resulting in nerve weakness, mainly if the group is located at the angle of the mandible.

Consequently, the facial nerve is impacted [4]. Careful and thoughtful observation is the key to discerning subtle signs of weakness in the

muscles supplied by the motor portion [5]. Evaluation of the severity and progression of facial nerve weakness is crucial and requires a reliable quantitative grading scale. Numerous scoring systems have been suggested for evaluating the degree of disfigurement [6]. In contrast to other scales, the Sunnybrook facial grading scale systematically evaluates each subunit of facial movement (eyebrows, eyelids, nasal base, upper lip, and lower lip) while subjects are instructed to make six simple facial expressions. In addition, the Sunnybrook facial grading scale globally assesses resting symmetry, symmetry of voluntary movement, and the degree of synkinesis, which are essential for physicians to clearly understand the progression and improvement of the disease [7]. Osteomas appear radiographically as circumscribed sclerotic masses. The treatment of choice is conservative surgical excision of the entire group and follow-up [8]. They are relatively rare in the jaws and can occur solely; however, multiple osteomas of the facial skeleton can give rise to specific disorders, such as Gardner's syndrome. It is an inherited autosomal dominant disorder characterized by various intestine adenomatous tumors with 100 % progression to colorectal adenocarcinoma and abnormalities of the bone, teeth, skin, retina, and other sites [9]. Genetic counseling is indicated to exclude any relation to the syndrome, and laboratory testing of peripheral leukocytes, a complete blood count, the carcinoembryonic antigen, liver function tests, and thyroid function tests are recommended for such patients [10].

This article highlights the transient weakness of the marginal mandibular nerve caused by the osteoma's constant pressure located at the mandible's angle along the course of the nerve.

Presentation of Case

A 15-year-old female patient was referred to the Alwasity Teaching Hospital/oral and maxillofacial surgery department and reported pain in the left cheek and swelling in the left side of the angle of the mandible and below the ear, which had been noticed six months

earlier (see **Figure 1**). Upon physical examination, the skin over the mass was intact; there was no ulceration or change in color; however, an ipsilateral asymmetry in the lower lip when smiling was observed. Palpation revealed a painful bony hard mass that almost reached 30*30 mm in size and was fixed to the underlying bone; ipsilateral submandibular lymphadenopathy was felt, no abnormality was observed during the intraoral examination, and no limitation in mouth opening was noticed.

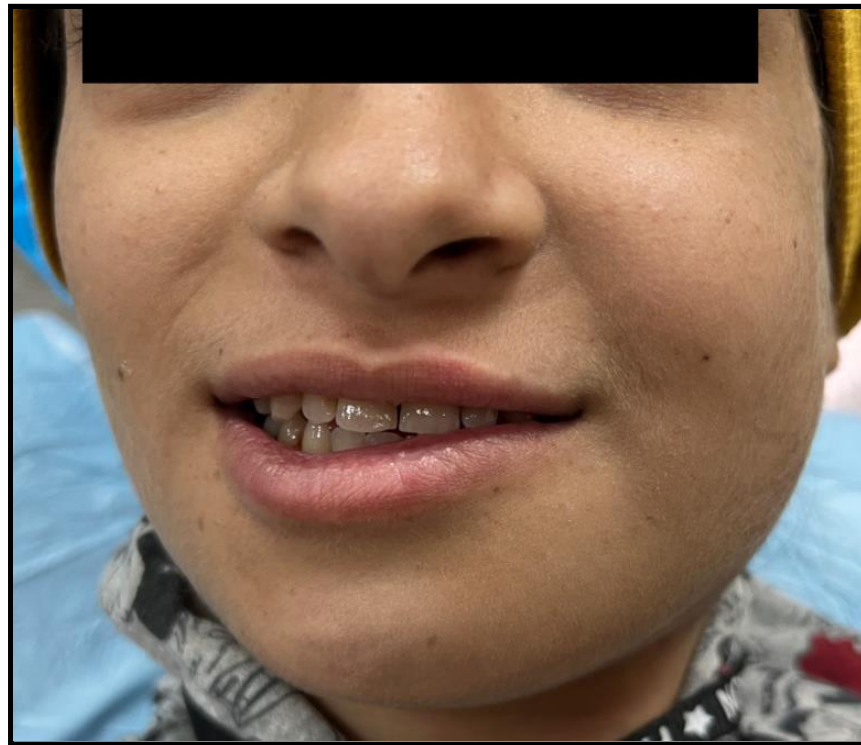

Figure 1. A pre-operative clinical picture demonstrates the asymmetry in the patient's smile.

A well-circumscribed radiopaque mass over the angle of the mandible on the left side was seen on the orthopantomogram (OPG), and the lower border of the mandible was intact. The computed tomography (CT) scan revealed a well-defined lobulated hyperdense mass

encircling the outer border of the mandibular angle, which extends from the tip of the mandible along the posterior wall of the ramus to the level of the sigmoid notch (see **Figure. 2**).

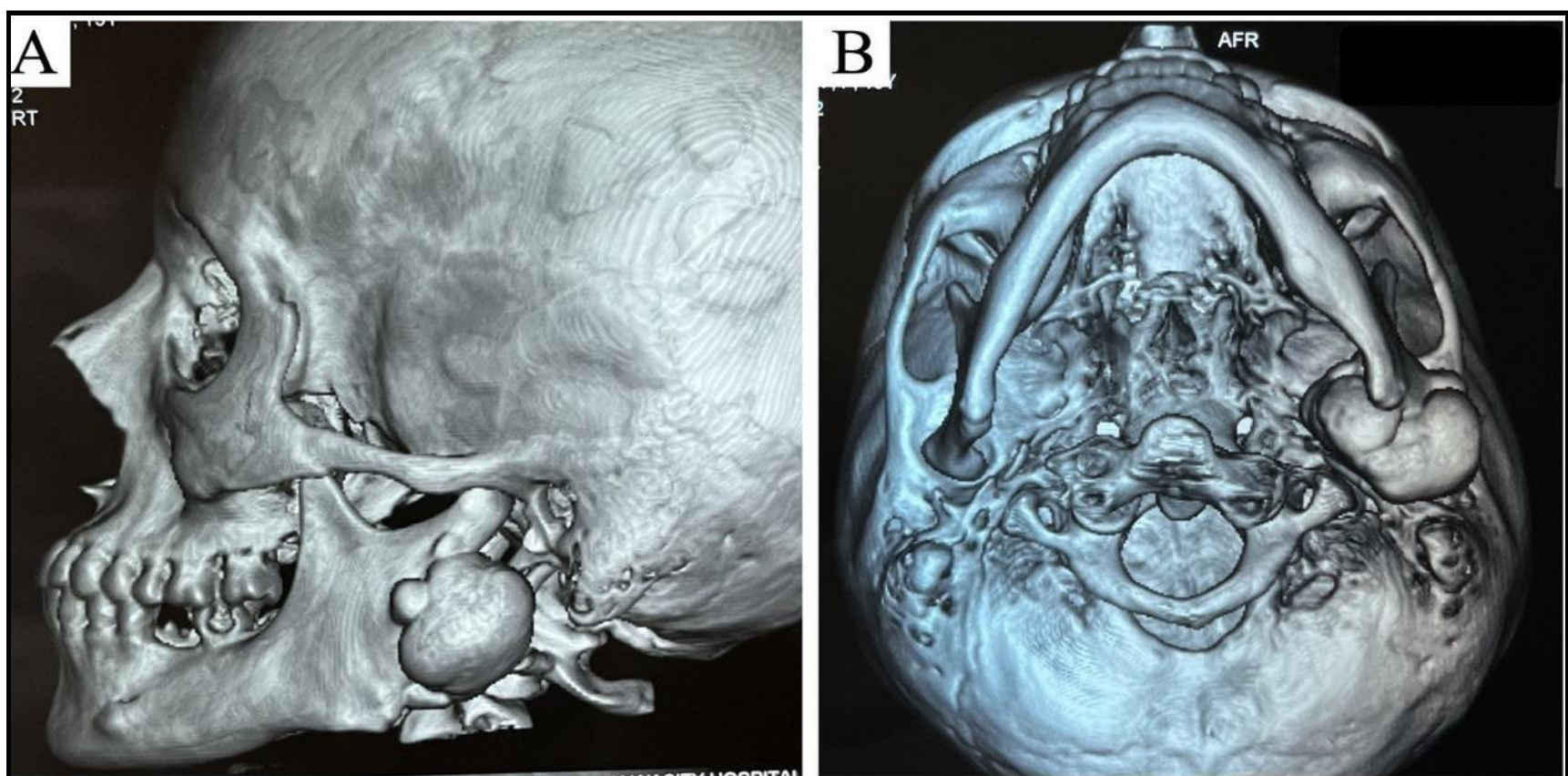


Figure 2. 3D C.T. scan views (A) demonstrate the osteoma's size and location from the patient's perspective. (B) shows the osteoma location from a posteroanterior standpoint.

The patient was referred to an orthopedic surgeon to evaluate any other osteomas in the long bones, which came back negative (see

Figure. 3). Also, the laboratory tests to detect the Gardner's syndrome were negative.

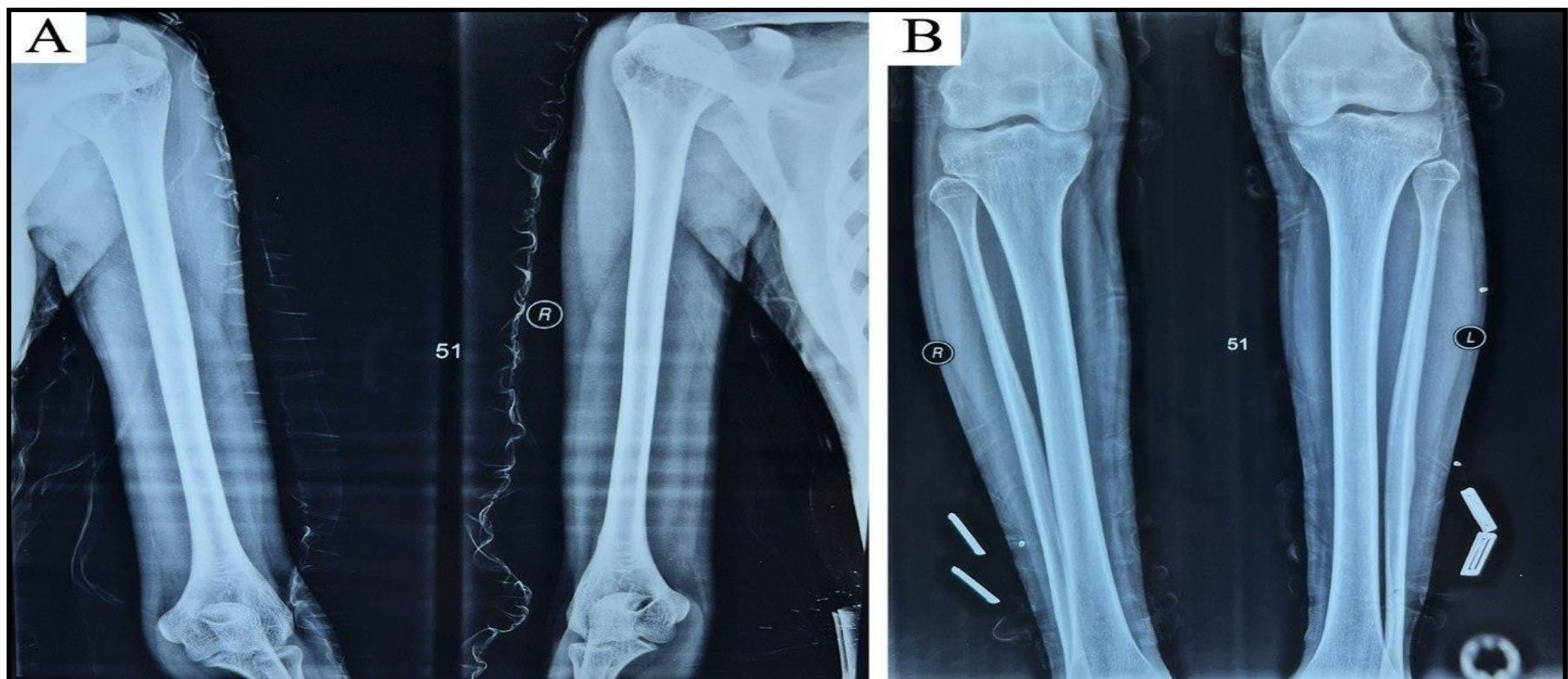


Figure 3. (A) Right and left posteroanterior radiograph of the patient's humerus demonstrates no osteoma. (B) right and left posteroanterior radiograph of the patient's tibia and fibula shows no osteoma.

The facial nerve represents the seventh cranial nerve (CN VII). It contains the motor, sensory, and parasympathetic (secretomotor) nerve fibers responsible for lacrimation, salivation, taste sensation in the anterior two-thirds of the tongue, and facial expression, and it also affects hearing [11]. It courses through the facial canal in the temporal bone and exits through the stylomastoid foramen. Then it enters the posteromedial surface of the parotid gland, passing laterally to the external carotid artery and the retromandibular vein, after which it divides into five terminal branches at the posterior edge of the parotid gland, these are the temporal, the zygomatic, the buccal, the marginal mandibular, and the cervical branches, then, they emerge from the anterior border of the gland and pass to the muscles of the face and the scalp [12]. In our case, we are focusing on the assessment of the marginal mandibular branch due to its motor innervation to the muscles of the lower lip, depressor labii inferioris, depressor anguli oris, the inferior fibers of the orbicularis oris and the mentalis

muscles, which draw the lower lip downward [11], in addition to its close approximation to the osteoma since the nerve runs forward and inferior to the angle of the mandible.

For the evaluation of the marginal mandibular nerve deficit, three follow-ups were done using the Sunnybrook Facial Grading System (SB) [13], which consists of three schemes: the first scheme observes the resting symmetry compared to the normal side; assessment is done by following any incomplete closure of the eyelashes, nasolabial folds, and mouth; then the patient is asked to smile, show teeth, or pull back the corners of the mouth to check for any asymmetry. The second scheme fits the symmetry of voluntary movement, which measures the degree of muscle excursion compared to the normal side. Assessment is done by asking the patient to wrinkle the forehead, gently close the eye, smile, snarl, and pucker the lips. The final scheme, synkinesis, measures the degree of involuntary muscle contraction associated with each expression (see Figure 4).

Sunnybrook Facial Grading System

Resting Symmetry	Symmetry of Voluntary Movement	Synkinesis																																																												
<p>Compared to normal side</p> <p>Eye (choose one only)</p> <p>normal 0</p> <p>narrow 1</p> <p>wide 1</p> <p>eyelid surgery 1</p> <p>Cheek (naso-labial fild)</p> <p>normal 0</p> <p>absent 2</p> <p>less pronounced 1</p> <p>more pronounced 1</p> <p>Mouth</p> <p>normal 0</p> <p>corner dropped 1</p> <p>corner pulled up/out 1</p> <p style="text-align: right;">Total <input type="checkbox"/></p> <p>Resting symmetry score Total × 5 <input type="checkbox"/></p>	<p style="text-align: center;">Degree of muscle EXCURSION compared to normal side</p> <p style="text-align: center;">Unable to initiate movement/no movement Initiates slight movement Initiated movement with mild excursion Movement almost complete Movement complete</p> <p>Standard Expressions</p> <table style="width: 100%; text-align: center;"> <tr> <td>Forehead Wrinkle (FRO)</td> <td>1</td><td>2</td><td>3</td><td>4</td><td>5</td> <td><input type="checkbox"/></td> </tr> <tr> <td>Gentle eye closure (OCS)</td> <td>1</td><td>2</td><td>3</td><td>4</td><td>5</td> <td><input type="checkbox"/></td> </tr> <tr> <td>Open mouth smile (ZYG/RIS)</td> <td>1</td><td>2</td><td>3</td><td>4</td><td>5</td> <td><input type="checkbox"/></td> </tr> <tr> <td>Snarl (LLA/LLS)</td> <td>1</td><td>2</td><td>3</td><td>4</td><td>5</td> <td><input type="checkbox"/></td> </tr> <tr> <td>Lip Pucker (OOS/OOI)</td> <td>1</td><td>2</td><td>3</td><td>4</td><td>5</td> <td><input type="checkbox"/></td> </tr> </table> <p style="text-align: center;">Gross Asymmetry Severe Asymmetry Moderate Asymmetry Mild Asymmetry Normal Symmetry</p> <p style="text-align: right;">Total <input type="checkbox"/></p> <p>Voluntary movement score: Total × 4 <input type="checkbox"/></p>	Forehead Wrinkle (FRO)	1	2	3	4	5	<input type="checkbox"/>	Gentle eye closure (OCS)	1	2	3	4	5	<input type="checkbox"/>	Open mouth smile (ZYG/RIS)	1	2	3	4	5	<input type="checkbox"/>	Snarl (LLA/LLS)	1	2	3	4	5	<input type="checkbox"/>	Lip Pucker (OOS/OOI)	1	2	3	4	5	<input type="checkbox"/>	<p style="text-align: center;">Rate the degree of INVOLUNTARY MUSCLE CONTRACTION associated with each expression</p> <p style="text-align: center;">NONE: No synkinesis or mass movement MILD: Slight synkinesis MODERATE: Obvious but not disfiguring synkinesis SEVERE: Disfiguring synkinesis/ Gross mass movement of several muscles</p> <table style="width: 100%; text-align: center;"> <tr> <td>0</td><td>1</td><td>2</td><td>3</td> <td><input type="checkbox"/></td> </tr> <tr> <td>0</td><td>1</td><td>2</td><td>3</td> <td><input type="checkbox"/></td> </tr> <tr> <td>0</td><td>1</td><td>2</td><td>3</td> <td><input type="checkbox"/></td> </tr> <tr> <td>0</td><td>1</td><td>2</td><td>3</td> <td><input type="checkbox"/></td> </tr> <tr> <td>0</td><td>1</td><td>2</td><td>3</td> <td><input type="checkbox"/></td> </tr> </table> <p>Synkinesis score: Total <input type="checkbox"/></p>	0	1	2	3	<input type="checkbox"/>	0	1	2	3	<input type="checkbox"/>	0	1	2	3	<input type="checkbox"/>	0	1	2	3	<input type="checkbox"/>	0	1	2	3	<input type="checkbox"/>
Forehead Wrinkle (FRO)	1	2	3	4	5	<input type="checkbox"/>																																																								
Gentle eye closure (OCS)	1	2	3	4	5	<input type="checkbox"/>																																																								
Open mouth smile (ZYG/RIS)	1	2	3	4	5	<input type="checkbox"/>																																																								
Snarl (LLA/LLS)	1	2	3	4	5	<input type="checkbox"/>																																																								
Lip Pucker (OOS/OOI)	1	2	3	4	5	<input type="checkbox"/>																																																								
0	1	2	3	<input type="checkbox"/>																																																										
0	1	2	3	<input type="checkbox"/>																																																										
0	1	2	3	<input type="checkbox"/>																																																										
0	1	2	3	<input type="checkbox"/>																																																										
0	1	2	3	<input type="checkbox"/>																																																										
<p>_____</p> <p>Patient's name</p> <p>_____</p> <p>Dx</p> <p>_____</p> <p>Date</p>	<p>Vol mov't score <input type="checkbox"/> - Resting symmetry score <input type="checkbox"/> - Synk score <input type="checkbox"/> = Composite score <input type="checkbox"/></p>																																																													

Figure 4: Sunnybrook Facial Grading System [13].

In the preoperative assessment, all of the reflexes were normal, except a drop in the corner of the mouth, mild asymmetry in the snarl, and moderate asymmetry in the smile and lip puckering, which were noticed.

The patient was operated on under general anesthesia with oral intubation and in the supine position. Surgical access to expose the mass was achieved via a submandibular incision. Dissection was carried out to reach the group without damaging the surrounding vital

structures by using a piezo surgery drill to excise the osteoma; the integrity of the outline of the angle and ramus was restored (see Figure. 5).

After one-month postoperatively, the drop in the corner of the mouth was present, as mild asymmetry in the smile, snarl, and lip puckering. The last follow-up was done after four months; all reflexes were normal except snarling, which was mild (see Figure. 6). The examination of ipsilateral lymph nodes was negative.

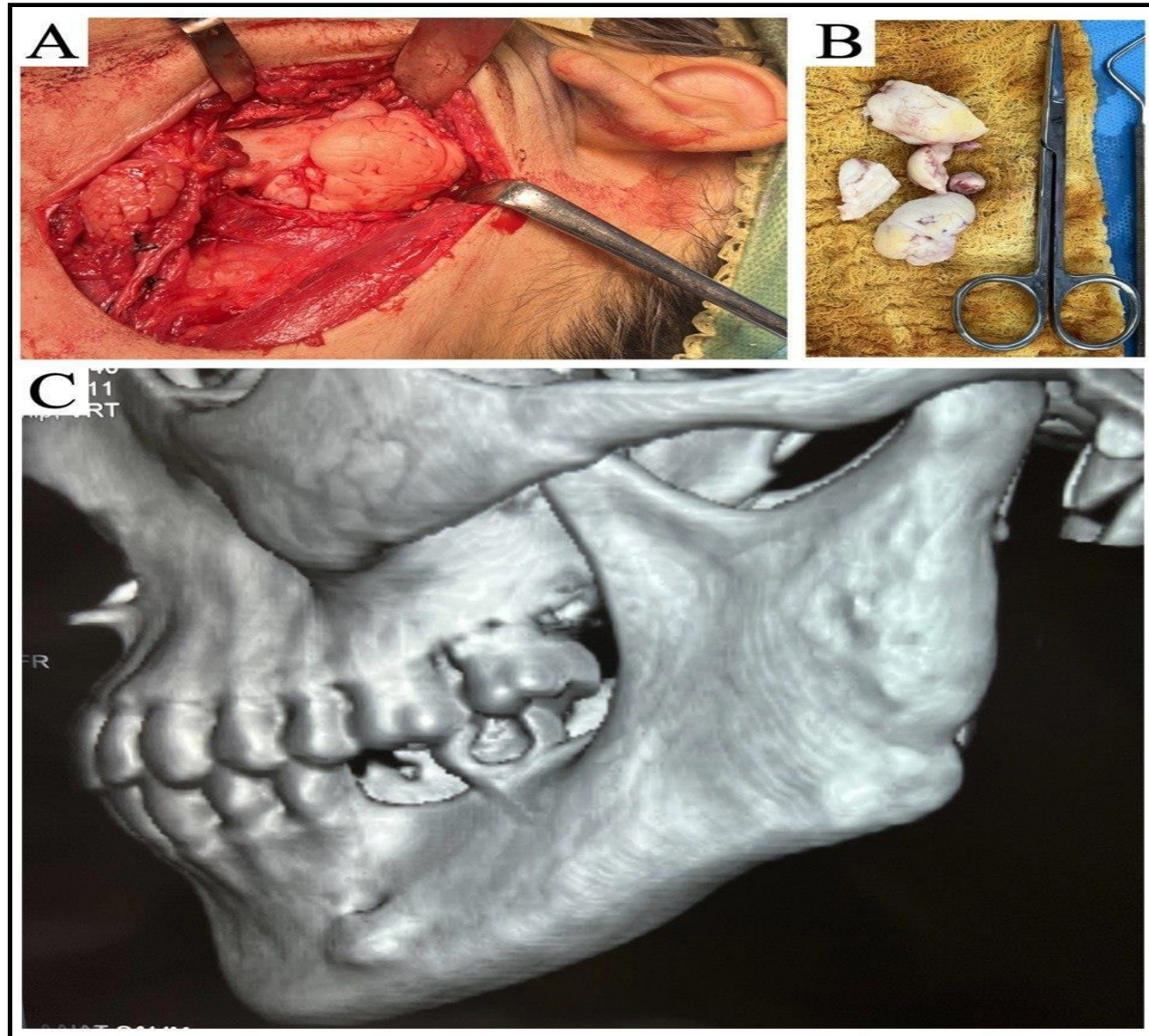


Figure 5. (A) An intraoperative picture of the osteoma. (B) osteoma after removal. (C) postoperative 3D CT.

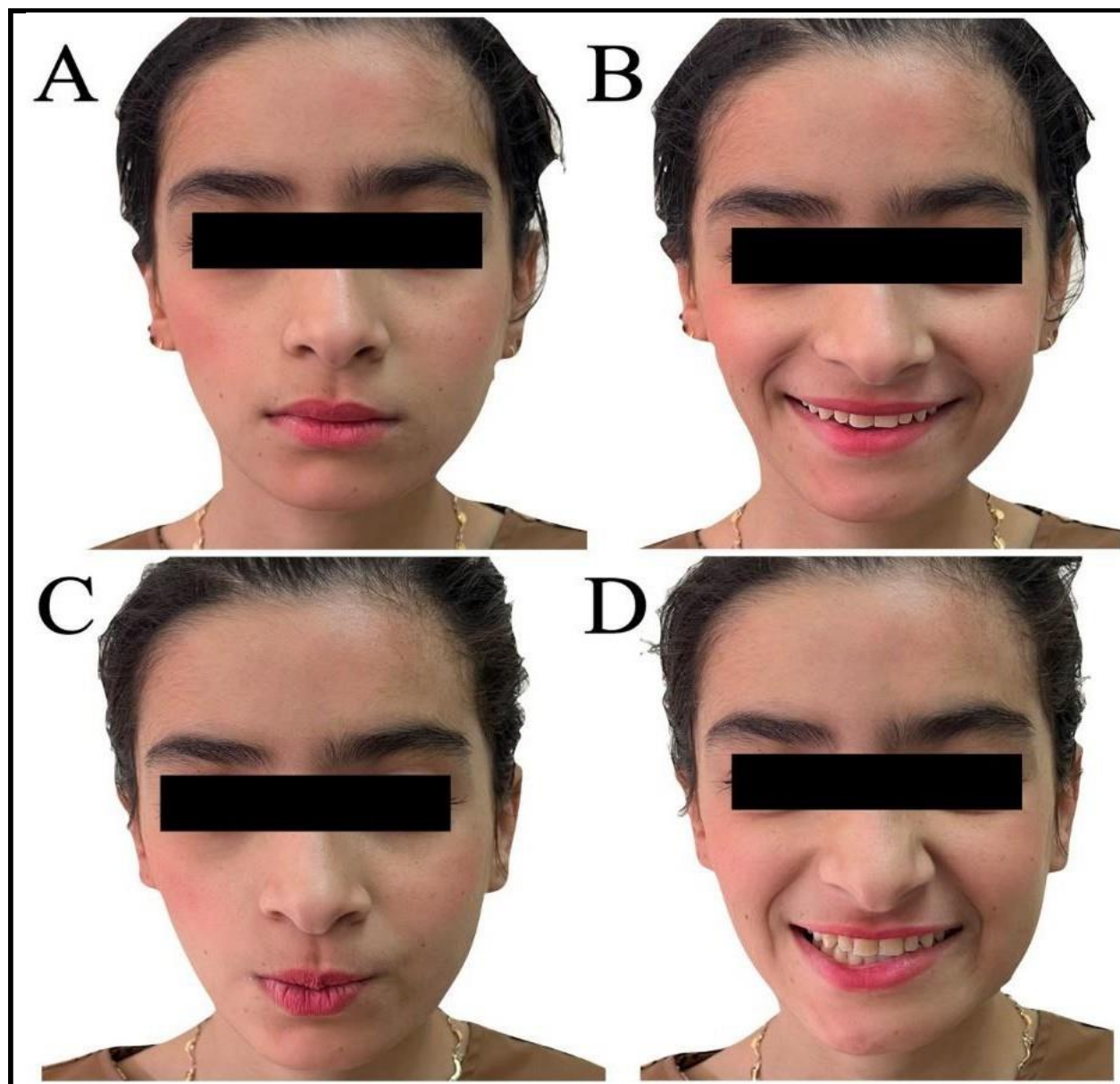

Fig. 6. Four-month postoperative clinical pictures. (A) patient in rest position. (B) patient is asked to smile. (C) patient is asked to pucker the lips. (D) patient in snurl position.

Discussion

Osteomas are uncommon, affecting an estimated 0.01-0.04 percent of the population [14]. They usually grow slowly via the continuous formation of bone. Tumors more significant than 30 mm diameter are considered giant tumors [15].

Osteomas' occurrence may be syndromic or non-syndromic [8]. They are usually asymptomatic and discovered by chance during routine radiological examinations. However, complications may occur due to progressive growth, bone expansion, facial deformity, and dysfunction [2]. In this study, the osteoma is giant, lobulated, and encircles the mandibular angle and ramus posteriorly, compressing the marginal mandibular nerve and causing nerve weakness and asymmetry in the patient's smile. Nevertheless, facial nerve involvement is sporadic. Since the facial canal is long and narrow, a tumor can put pressure on the nerve, resulting in damage either by direct mechanical injury or by reducing blood flow [16], which requires early recognition and intervention to discern subtle signs of weakness of muscles supplied by the motor portion. It can be noted in the nasolabial folds and corners of the mouth (The affected side droops and participates manifestly less in speaking) [5]. Therefore,

Conclusion

Facial nerve weakness due to the compression of a giant tumor is extremely rare; it causes, in our study, asymmetry in the patient's smile and can affect a person's ability to convey emotion. Such conditions require early recognition and management. Relying on the Sunnybrook Facial Grading System (SB) to assess the marginal mandibular nerve weakness gave us a clue about the improvement in the patient's smile after the complete osteoma removal.

References

1. Cotran RS, Robbins SL. Pathologic basis of disease. In Pathologic basis of disease 2013 (pp. 1400-1400).
2. Durão AR, Chilvarquer I, Hayek JE, Provenzano M, Kendall MR (2012) Osteoma of the zygomatic arch and mandible: report of two cases. *Revista Portuguesa de Estomatologia, Medicina Dentária e Cirurgia Maxilofacial*. 53(2): 103-107.
3. Revankar SM. Daanava region with 12 zodiac sign. Blue Rose Publishers; 2021 Oct 7.
4. Curtis K, Bance M, Carter M, Hong P (2014) Middle ear osteoma causing progressive facial nerve weakness: a case report. *Journal of Medical Case Reports*. 8: 310.
5. Walker HK, Hall WD, Hurst JW. Clinical methods: the history, physical, and laboratory examinations.
6. Meng-yao Z, Guo-dong F, Zhi-qiang G (2008) Facial grading system: physical and psychological impairments to be considered. *Journal of Otolaryngology*. 3(2): 61-7.
7. Jirawatnotai S, Jomkoh P, Voravitvet TY, Tirakotai W, Somboonsap N (2021) Computerized Sunnybrook facial grading

evaluation of the severity and progression of facial weakness is crucial and requires a reliable quantitative grading scale. Numerous scoring systems have been suggested for evaluating the degree of disfigurement [7].

The Sunnybrook Facial Grading System (SB) is a well-established scale for assessing facial movement outcomes as it systematically evaluates each subunit of facial movement (eyebrows, eyelids, nasal base, upper lip, and lower lip). It was proposed by Ross et al. in 1996. It's a regional weighted scale based on evaluating different regions, including resting symmetry, voluntary movement symmetry, and synkinesis severity. Assessment of these reflexes provides valuable additional information about facial nerve function [6].

Treatment is indicated for osteomas that are symptomatic or cosmetically unacceptable. Excision or drilling of superficial osteomas is a simple procedure [8]. Approximately four months postoperatively, normal symmetry was achieved in the smile and lip puckering, and there was no dropping in the corner of the mouth; however, a mild snarl is still present.

Conflicts of interest: The author reports no potential conflicts of interest.

Funding: None.

Consent: Written informed permission was obtained from the patient to publish this case report and any accompanying images.

Acknowledgments: We thank Dr. Ali Shather for their practical suggestions.

- scale (SBface) application for facial paralysis evaluation. *Archives of Plastic Surgery*. 48(3): 269-277.
8. Das AK, Kashyap RC (2005) Osteoma of the mastoid bone-a case report. *Medical Journal Armed Forces India*. 61(1): 86-87.
9. Gawande P, Deshmukh V, Garde JB (2015) A giant osteoma of the mandible. *Journal of Maxillofacial and Oral Surgery*. 14(2): 460-5.
10. Charifa A, Jamil RT, Zhang X (2022) Gardner syndrome. In StatPearls [Internet]. StatPearls Publishing.
11. Sonne J, Lopez-Ojeda W (2022) Neuroanatomy, cranial nerve. In StatPearls [Internet]. StatPearls Publishing.
12. Al-Qahtani K, Mlynarek A, Adamis J, Harris J, Seikaly H, et al. (2015) Intraoperative localization of the marginal mandibular nerve: a landmark study. *BMC research notes*. 8:382.
13. Neely JG, Cherian NG, Dickerson CB, Nedzelski JM (2010) Sunnybrook facial grading system: reliability and criteria for grading. *The laryngoscope*. 120(5): 1038-45.
14. Ozturk H, Torul D, Yuceer E, Karli R, Baris S (2018) Peripheral osteoma of mandibular angulus: Analysis of the literature and

- report of a new case. *Odvotos-International Journal of Dental Sciences*. 20(2): 61-70.
15. Cheng KJ, Wang SQ, Lin L (2013) Giant osteomas of the ethmoid and frontal sinuses: Clinical characteristics and review of the literature. *Oncology letters*. 5(5): 1724-1730.
16. Mumtaz S, Jensen MB (2014) Facial neuropathy with imaging enhancement of the facial nerve: A case report. *Future neurology*. 9(6): 571-576.